

Effect of Intra-operative Saline Irrigation during Burr Hole Surgery on the Recurrence for Chronic Subdural Hematomas

Chungnam Lee, Dong Sun Park, Sang Woo Song, Young Il Chun, Joon Cho, Chang Taek Moon, Young-Cho Koh

Department of Neurosurgery, Konkuk University School of Medicine, Seoul, Korea

Objective: The aim of this study is to compare the postoperative recurrence rates and alteration in follow-up brain CT radiographic results between patients with chronic subdural hematoma (CSDH) treated by burr hole trephination with or without irrigation during the surgery.

Methods: A total of 100 patients diagnosed with CSDH underwent burr hole trephination from January 2013 to May 2015. The patients were divided into two groups: those who underwent intra-operative saline irrigation and those who did not. Difference in the rate of symptomatic recurrence requiring second surgery between the two groups was evaluated. Radiographic results were analyzed based on the patients' follow-up brain CTs taken 1 month after the surgery.

Results: Sixty eight patients underwent intra-operative irrigation while 32 patients did not. The median ages of the two groups were 69.6 years (range, 39-91 years) and 69.1 years (range, 38-86 years), respectively. Among the "irrigated" group, six patients required second surgery due to recurrent hematoma (8.8%) while nine patients in the "not irrigated" group underwent second surgery (28.1%). Difference in the Glasgow coma scale (GCS) between the two groups had no statistical significance.

Conclusion: Upon conducting burr hole trephination surgery for CSDH, saline irrigation is a simple procedure that can reduce the recurrence rate.

Key Words: Chronic subdural hematoma • Trephining • Therapeutic irrigation

INTRODUCTION

Chronic subdural hematoma (CSDH) is one of the most common conditions encountered concerning neurosurgical interventions^{4,5}. Although CSDH is a curable disease with low morbidity and mortality rates, the high rate of symptomatic recurrence is a challenge in the neurosurgical practice⁴. The rate of recurrence of CSDH after surgery is known to be around 9.2% to 26.5%¹³. The treatment of choice for symptomatic CSDH is surgical evacuation, which usually results in marked neurologic and radiographic improvement¹⁰. Although the modes of surgical treatment ranges widely from burr hole trephination to complex craniotomy with membranectomy, in the recent years, burr hole trephination has replaced the conventional craniotomy in most of the CSDH cases for many reasons such as minimal invasiveness, lower mortality and morbidity, and shorter length of hospital stay¹⁰. There have been

many attempts to reduce the recurrence rate of CSDH following burr hole surgery.

In the present study, the authors have compared the postoperative recurrence rates of burr hole trephination depending on the inclusion of intraoperative saline irrigation procedure. The extent of hematoma resolution based on the follow-up CT scans has also been compared.

MATERIALS AND METHODS

The charts of all adult CSDH patients above 18 years of age who underwent surgical evacuation in a single center were retrospectively reviewed. Initial diagnoses of 100 patients with symptomatic CSDH were made by computed tomography (CT) scans. All the patients had previous history of head trauma. We categorized the patients under two groups, "irrigated" and "not irrigated" depending on the inclusion of intra-operative saline irrigation of the CSDH.

All the patients underwent burr-hole trephination, dura incision and subdural catheter placement. As for the "irrigated" group, warm sterile saline was irrigated through the subdural catheter, about 20 to 50 mL at a time, and then let to drain. The irrigation process was repeated until the drained irrigant

Corresponding author: **Dong Sun Park**, MD
Department of Neurosurgery, Konkuk University School of Medicine,
120-1 Neungdong-ro, Gwangjin-gu, Seoul 05030, Korea
Tel: +82-2-2030-7357, Fax: +82-2-2030-7359
E-mail: 20110076@kuh.ac.kr

Table 1. Comparison of retreatment and radiographic resolution rates between the "irrigated" and "not irrigated" groups

		Patient number (%)		Total	p [§]	β (SE)	OR ^{**}	95% CI ^{††}
		Not irrigated	Irrigated					
Retreatment	Yes	9 (28.1)	6 (8.8)	15 (15.0)	0.0170*	1.397 (0.581)	4.04	1.23-12.6 [†]
	No	23 (71.9)	62 (91.2)	85 (85.0)				
Radiographic results	Resolution	16 (50.0)	50 (73.5)	66 (66.0)	0.0205 [†]	1.022 (0.448)	2.78	1.16-6.68 [†]
	Residual [†]	16 (50.0)	18 (26.5)	34 (34.0)				

*: Statistical analysis was performed with Fisher's exact test, †: Statistical analysis was performed with Chi-square test, ††: For statistical analysis, we used the binominal logistic regression analysis.

§p: p-value, ||SE: standard error, **OR: odds ratio, ††CI: confidence interval.

appeared almost clear in color. The drain was then connected to an external ventricular drainage bag which was kept in a dependent position for more than 48 hours (3.12±1.01 days). For the "not irrigated" group, the irrigation procedure was omitted but all other surgical procedures and post-operative managements were identical.

The first CT was taken immediately after the surgery, and following CT's were taken prior to the removal of the catheter (3.12±1.01 days) and one month after the surgery, at the outpatient clinic. Patients were discharged home or to a local hospital after catheter removal and when they no longer needed specialized neurosurgical care (8.26±2.09 days).

The outcome between the two groups was evaluated in terms of recurrence, where second surgery was required to treat recurrent CSDH.

Radiographic outcome was evaluated with the follow-up CT results, where remnant CSDH or subdural hygroma of more than 0.5 times the skull vault thickness was termed "residual" and lesser amount was termed "resolved".

1. Statistical Analysis

Repeated measure analyses were used to compare the relationship of outcomes between the two groups. Fisher's exact test and Chi-square test were executed at the significance level of <0.05. For the statistically significant cases, logistic regression was also used find significant relationship between both groups.

RESULTS

The study population was composed of 100 subjects, and the median age was 72.5 years old (range, 3-91 years) There was male preponderance, with 74 male and 26 female patients (ratio=2.85:1). The patients' presenting symptoms included hemiparesis, headache, and mental change, and their mean GCS at admission was 13.1 (range, 7-15). Eighty-five patients had unilateral CSDH, while 15 had bilateral CSDH. Concer-

Table 2. Comparison of GCS^{*} improvement between "irrigated" and "not irrigated" groups

	Initial GCS	Final GCS	GCS improvement (mean±SD [†])	p-value
Not irrigated	13.2	14.6	1.41±0.62	0.444 [†]
Irrigated	13.0	14.6	1.54±0.92	

*GCS: Glasgow coma scale, †SD: standard error, †: Statistical analysis was performed with T-test.

ning CSDH laterality, there was left side preponderance, with 52 left sided and 33 right sided hematomas (ratio=1.58:1). Five cases (10.6%) of left sided hematomas and 8 cases (32.0 %) of right sided hematomas required second surgery due to recurrence, but this was insignificant (p=0.07).

A total of six surgeons were involved in this study and the rate of irrigation applied by each surgeon was 42%, 44%, 62%, 67%, 83%, and 83%, respectively.

Intra-operative irrigation was done in 68 patients, while the procedure was omitted in 32 patients. The mean age of the patients in the "irrigated" group was 69.6 years (range, 38-86 years), while the mean age was 69.1 years (range, 39-91 years) for the "not irrigated" group. In overall, 15 patients (15%) underwent second surgery due to recurrence. Six patients (8.8 %) in the "irrigated" group and 9 patients (28.1%) in the "not irrigated" group necessitated second surgery due to recurrence (p=0.02). Association analysis showed that there were 4.04 higher chance of recurrence in the "not irrigated" group (p=0.02, OR=4.04, 95% CI=1.23-12.6) (Table 1).

In the follow-up CT taken 1 month after the surgery, 66 patients showed total resolution whereas 34 patients had residual hygroma or CSDH. Eighteen patients in the "irrigated" group (26.5%) and 16 patients in the "not irrigated" group (50%) had residual hematoma in the follow-up CT, and the difference between the two groups was statistically significant (p=0.02). Association analysis showed that the "irrigated" group had 2.78 times higher chance of hematoma resolution at the follow-up CT (p=0.02, OR=2.78, 95% CI=1.16-6.68).

The GCS was evaluated at admission and before discharge, and the change in these values was analyzed. The mean GCS

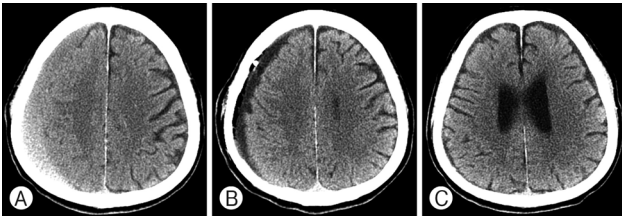


Fig. 1. Computed tomography of a 80-year-old male with chronic subdural hematoma treated by burr hole trephination with saline irrigation. (A) Preoperative CT shows chronic subdural hematoma. (B) Immediate-postoperative CT shows diluted residual subdural fluid after irrigation. (C) Postoperative CT 1 month after surgery shows total resolution.

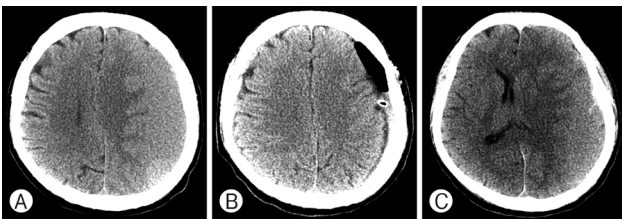


Fig. 2. Computed tomography of a 66-year-old male with chronic subdural hematoma treated by burr hole trephination without saline irrigation. (A) Preoperative CT shows chronic subdural hematoma. (B) Immediate postoperative CT shows residual hematoma. (C) Postoperative CT 1 month after surgery shows recurrent CSDH with mass effect.

score improvement in the “irrigated” group was 1.54 ± 0.92 , whereas the value was 1.41 ± 0.62 in the “not irrigated” group. However, there was no statistical significance ($p=0.45$). The data is specified in Table 2, and illustrative cases from each group are presented in (Fig. 1 and 2.)

DISCUSSION

Chronic subdural hematoma (CSDH) is one of the most common conditions encountered in neurosurgical interventions^{4,5}. The number of CSDH is increasing in developed countries⁶, and it is common among elderly patients, and its incidence is 58/100,000 for elderly population aged above 70 years, about 12 times higher than the general population¹³. About 60-80% of the patients with CSDH had history of head injuries. However, variation is possible because most head injuries leading to CSDH are trivial: these events are easily forgotten or not actually considered important by patients¹³. Treatment of choice for symptomatic CSDH is surgical evacuation, which usually results in marked neurologic and radiographic improvement¹⁰. The modes of surgical treatment ranges from burr hole trephination to complex craniotomy with membranectomy. The most common surgical treatments include twist drill cra-

niotomy, burr hole trephination, and craniotomy, result in differing degrees of reoperation rates from 5% to 27.8%⁹. The rate of recurrence varied in many literature reviews. In the literature, the re-operation rate for CSDH treated with burr hole trephination was 6.6%, which proved significant from the 24.1% among craniotomy patients⁹. Secer et al. presented that symptomatic recurrence of CSDH has been noted in 8%-37%¹¹. Generally, burr hole trephination reduced recurrence and re-operation⁶, and it has been the most preferred technique in treating patients with CSDH⁵. In the recent years, burr hole trephination has replaced the conventional craniotomy in most of the CSDH cases for many reasons such as less invasiveness, lower mortality and morbidity, shorter length of hospital stay, and overall patient satisfaction¹⁰.

The recurrence rate of CSDH may differ according to individual characteristics of each patient, pathogenesis of CSDH, and surgical procedure. Patients' characteristics include factors such as age, alcoholism, and coagulation disorders¹¹.

There have been many attempts to reduce the recurrence rate of CSDH, and various surgical and post-operative management styles and techniques are practiced by many neurosurgeons according to their preference. These include one or two burr hole trephination, using or not using intra-operative saline irrigation, open or closed drainage system, etc^{4,11}. In the present study, the primary goal was geared towards comparison of burr-hole trephination with and without intra-operative irrigation in treating CSDH. Several papers analyzed the outcomes of CSDH treatment depending on whether or not irrigation was done. Kumar et al. reported that burr hole trephination with saline irrigation is a simple, fast, and safe procedure for treating CSDH with a favorable outcome⁵. In the other literature, Gurelik et al. reported that there was no significant difference between the recurrence rates in the irrigation group and in the no-irrigation group³. Erol et al. stated that there was no difference in recurrent rates between the two groups, but burr hole with irrigation was more effective when recovery rates and postoperative complication are concerned¹.

Although there were differences in the results of previous studies, the authors found statistically significant differences in the retreatment rates between both groups of patients undergoing burr hole trephination to treat CSDH.

There are several factors associated with increased recurrence rate. Firstly, the thick remnant hemorrhagic fluid may act as a dead space, and this can cause an impaired adhesion between the inner and outer neo-membranes and promote the recurrence of CSDH⁸. After this subdural space had been created, cells in the dural border begin to proliferate, representing the first step in the pathogenesis of CSDH. Mori et al.

presented that persistence of an enlarged subdural space, or poor re-expansion of the brain, in patients undergoing evacuation of CSDH creates the potential for reaccumulation of the hematoma⁷. By irrigation, the authors speculated that quicker drainage of the diluted hemorrhagic fluid and elimination of dead space would be possible, in turn would result in quicker brain re-expansion and thus lower the chance of recurrence.

Secondly, the contents of the hematoma itself may act as inducing factors for recurrent hematoma formation^{2,12}. Shono et al. explained that the high concentration of VEGF within the hematoma could induce neovascularization with abnormally dilated sinusoids and incomplete basement membrane which allows excessive permeability and hence increase the rebleeding risk¹². The CSDH fluid is also rich in inflammatory mediators such as kallikrein, bradykinin, and platelet-activating factor. After initial trauma, the sequence of events in the natural course of the CSDH consists of local inflammation². Further inflammation caused by the release of these proinflammatory factors create a self-enhancing vicious cycle that is responsible for frequent rebleeding and enlargement of the CSDH². High levels of fibrin degradation products (FDP) within the CSDH fluid is also known to promote recurrent hematoma formation by increasing tissue plasminogen activator and affecting the coagulation cascade; activated plasmin depletes coagulation factors to produce more FDPs and the vicious cycle is continued, resulting in increased bleeding risk of the defective neovasculature. By intra-operative hematoma irrigation with saline, much of these angiogenic, proinflammatory and anticoagulatory factors are physically washed away, and their effect in promoting rebleeding are expected to be minimized¹¹.

There are a number of limitations in our study. First, the study was conducted retrospectively and is therefore subject to potential sources of bias and variation. Subsequently, the choice of the procedure was decided by each surgeon's preference rather than by randomization. Second, some of the widely accepted predisposing factors such as the patient age and underlying conditions such as alcoholism and diabetes mellitus, and other coagulopathies have not been taken into consideration in the present study. Thus, further well-designed randomized prospective studies with larger study samples may be needed to further support our arguments and reach other important findings concerning the recurrence of CSDH.

CONCLUSION

Based on the results of this study, the authors believe that burr hole trephination for CSDH present different clinical and radiographic results depending on the use of saline irrigation.

Intra-operative saline irrigation reduced recurrence and retreatment rate, as well as the resolution rate in the CT scan. However, there was no significance concerning the GCS change between the two groups. Consequently, it can be implied that burr hole trephination with irrigation may be a simple and effective method in reducing recurrence and retreatment in CSDH.

REFERENCES

1. Erol FS, Topsakal C, Ozveren MF, Kaplan M, Tiftikci MT: Irrigation vs. closed drainage in the treatment of chronic subdural hematoma. *J Clin Neurosci* 12:261-263, 2005
2. Frati A, Salvati M, Mainiero F, Ippoliti F, Rocchi G, Raco A, et al: Inflammation markers and risk factors for recurrence in 35 patients with a posttraumatic chronic subdural hematoma: a prospective study. *J Neurosurg* 100:24-32, 2004
3. Gurelik M, Aslan A, Gurelik B, Ozum U, Karadag Ö, Kars HZ: A safe and effective method for treatment of chronic subdural haematoma. *Can J Neurol Sci* 34:84-87, 2007
4. Javadi A, Amirjamshidi A, Aran S, Hosseini SH: A randomized controlled trial comparing the outcome of burr-hole irrigation with and without drainage in the treatment of chronic subdural hematoma: a preliminary report. *World Neurosurg* 75:731-736; discussion 620-733, 2011
5. Kumar P, Kiran U: Management of chronic subdural haematoma: Single burr-hole drainage and irrigation using the technique of "syringing". *Ind J Neurotr* 10:105-108, 2013
6. Mondorf Y, Abu-Owaimer M, Gaab MR, Oertel JM: Chronic subdural hematoma-craniotomy versus burr hole trepanation. *Br J Neurosurg* 23:612-616, 2009
7. MORI K, MAEDA M: Surgical treatment of chronic subdural hematoma in 500 consecutive cases: clinical characteristics, surgical outcome, complications, and recurrence rate. *Neurol Med Chir* 41:371-381, 2001
8. Ohba S, Kinoshita Y, Nakagawa T, Murakami H: The risk factors for recurrence of chronic subdural hematoma. *Neurosurg Rev* 36:145-150, 2013
9. Regan JM, Worley E, Shelburne C, Pullarkat R, Watson JC: Burr hole washout versus craniotomy for chronic subdural hematoma: patient outcome and cost analysis. *PloS One* 10, 2015
10. Santarius T, Kirkpatrick PJ, Ganesan D, Chia HL, Jalloh I, Smielewski P, et al: Use of drains versus no drains after burr-hole evacuation of chronic subdural haematoma: a randomised controlled trial. *Lancet* 374:1067-1073, 2009
11. Seçer M, Kalyoncu N, Günal M, Kuruoğlu E: Comparison of Burr Hole Irrigation and Closed System Drainage Methods After Burr Hole Irrigation in The Treatment of Chronic Subdural Hematoma. *J Neurolog Sci* 29, 2012
12. Shono T, Inamura T, Morioka T, Matsumoto K-i, Suzuki SO, Ikezaki K, et al: Vascular endothelial growth factor in chronic subdural haematomas. *J Clin Neurosci* 8:411-415, 2001
13. Singh AK, Suryanarayanan B, Choudhary A, Prasad A, Singh S, Gupta LN: A prospective randomized study of use of drain versus no drain after burr-hole evacuation of chronic subdural hematoma. *Neurol India* 62:169, 2014